

Efficacy of Infrainguinal vs Suprainguinal Approach to Fascia Iliaca Compartment Block for Postoperative Analgesia in Patients with Proximal Femoral Fracture: A Randomised Clinical Study

K JUBAIRIYA¹, PK FARHA², NEERA VALSAN³, MOONA⁴, PAUL O RAPHAEL⁵,
AJ SUKANYA PRINCE MARY⁶, P ANUSREE⁷, SM MOHAMMED NABEEL⁸



ABSTRACT

Introduction: The Fascia Iliaca Compartment Block (FICB) has been useful in postoperative pain management for surgeries involving the hip joint and femur. Under ultrasound guidance, one can approach this compartment using either the conventional infrainguinal or suprainguinal methods. The suprainguinal approach was expected to be better due to the more proximal placement of the drug.

Aim: To compare the suprainguinal and infrainguinal approaches to FICB for postoperative analgesia in proximal femur fractures.

Materials and Methods: This unicentric prospective randomised double-blind clinical study was conducted over six months following approval from the ethics committee and in accordance with the Clinical Trial Registry of India (CTRI/2022/12/048121). A total of 60 patients were randomly divided into two groups of 30 using computer-generated random numbers. FICB was performed in the preoperative area with either approach under ultrasound guidance depending on the assigned group. Surgery was performed under a subarachnoid block after 30 minutes.

Postoperative pain was assessed using the Visual Analogue Scale (VAS) score. If the VAS score was greater than 4, rescue analgesia was administered with intravenous paracetamol 1 gm infusion. The incidence of postoperative delirium was also recorded.

Results: The duration of postoperative analgesia was significantly longer in the suprainguinal group (Group S) (481.7 ± 136.7 minutes) compared to the infrainguinal group (Group I) (385.2 ± 99.39 minutes) (p -value=0.001). The VAS score was similar between the groups at 2, 6, and 12 hours. However, the VAS score was significantly lower in Group S (2.333 ± 0.479) compared to Group I (2.867 ± 1.196) at 24 hours. The incidence of postoperative delirium was comparable in both groups (p -value=0.754).

Conclusion: Regarding the duration of analgesia and reduced pain intensity at 24 hours, suprainguinal FICB was more effective than infrainguinal FICB in managing pain. There were no significant differences in overall paracetamol intake and the incidence of delirium between the two groups.

Keywords: Analgesia, Ropivacaine, Ultrasound

INTRODUCTION

The most common site of fractures in elderly patients is the proximal femur [1]. Perioperative pain management in these patients is a challenge for the anaesthesiologist. Severe pain may lead to postoperative delirium and delayed recovery [2]. Multimodal analgesia has been used for postoperative pain management [3,4]. Studies have proven that peripheral nerve blocks offer better analgesia with fewer adverse effects than opioids and Non Steroidal Anti-Inflammatory Drugs (NSAIDs) in the geriatric population [5,6]. The lumbar plexus descends into the pelvis, where the femoral nerve, lateral femoral cutaneous nerve, and obturator nerve meet in a small compartment just below the fascia iliaca. These nerves branch and diverge from one another as they descend towards the inguinal region. Therefore, drug distribution well above the inguinal ligament is preferred to reach these nerves with a single injection of the local anaesthetic [7]. The fascia iliaca compartment can be approached under ultrasound guidance with the conventional infrainguinal approach or the suprainguinal approach. The suprainguinal approach would enable the local anaesthetic to block the lumbar plexus at a level higher than the infrainguinal approach, thereby blocking the ilioinguinal, iliohypogastric,

and genitofemoral nerves that originate from the L1 and L2 anterior rami. This higher-level approach is expected to provide better analgesia compared to the conventional infrainguinal approach [8].

There is a dearth of studies looking at the comparison between the conventional infrainguinal approach and the suprainguinal approach for postoperative analgesia, comparing the duration of analgesia and the incidence of postoperative delirium. The few studies that compared these two approaches looked at the use of postoperative morphine or tramadol as rescue analgesia [8,9]. The use of other analgesics, including paracetamol, as rescue analgesia has not been studied in detail in any of these trials. Thus, the present study aimed to compare the effectiveness of two distinct approaches for postoperative analgesia in patients undergoing proximal femoral fracture reduction under subarachnoid block. This study also compared the dose of paracetamol used as rescue analgesia and the incidence of delirium in both approaches. Although the suprainguinal approach was theoretically superior, there was insufficient clinical evidence to support this theory [9]. This study hypothesised that suprainguinal FICB would be more effective than infrainguinal FICB in providing postoperative analgesia.

MATERIALS AND METHODS

The randomised double-blind clinical trial was conducted at Malabar Medical College Hospital and Research Centre, a tertiary care hospital in Calicut, Kerala, India from November 2023 to April 2024. The study was initiated after obtaining the approval of the Institutional Ethics Committee (IEC) (MMCH&RC/IEC/2022/10/61) and registering in the CTRI (CTRI/2022/12/048121). This study was conducted as per the Helsinki II declaration and reported following the CONSORT 2010 guidelines.

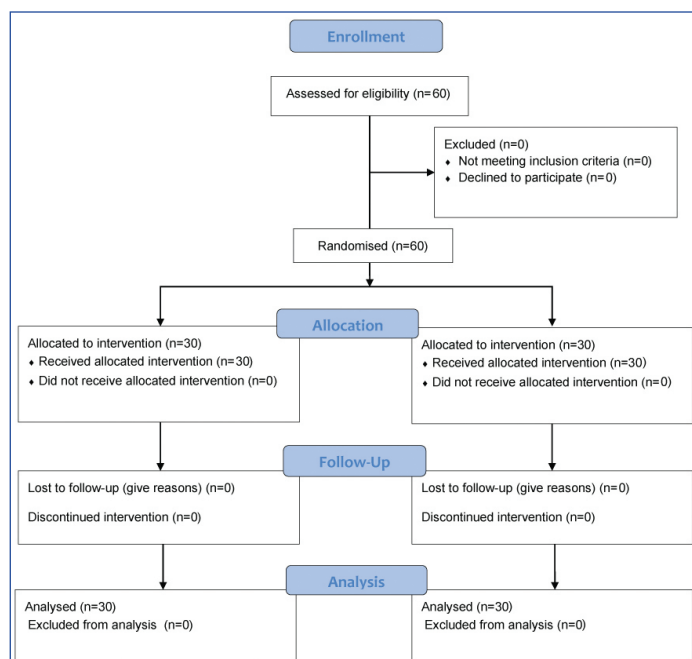
Inclusion criteria: A total of 60 patients with American Society of Anaesthesiologists (ASA) physical statuses I, II, and III with proximal femoral fractures undergoing surgical reduction under subarachnoid block were included in the study.

Exclusion criteria: Patients with a history of hepatic or renal diseases, allergy to local anaesthetics, and a history of bleeding diathesis were excluded from the study.

Sample size: The sample size was calculated from a previously published study by Fujihara Y et al., using the mean and standard deviation of the VAS score at different time intervals with 90% power and a 1% level of significance [6]. The minimum sample size calculated was 28 per group. The group size of 30 was determined by power analysis based on standard deviation data from previously published reports [6].

Study Procedure

Patients were randomly divided into two groups (group I-Intrainguinal group and group S-Suprainguinal group) by a computer-generated table of random numbers. An anaesthesiologist, who was not directly involved in patient care, opened the envelope for dividing the groups. Postoperative pain scores and 24-hour paracetamol consumption were assessed by the duty anaesthesiologist [Table/Fig-1]. A pre-anaesthetic check-up, a detailed medical history, and a systemic examination were done. After explaining in detail about the study, written informed consent was taken from patients and bystanders. All patients were educated preoperatively about the VAS for pain (0=no pain, 10=the worst pain).



[Table/Fig-1]: Study protocol [Consolidated standards of reporting trials] CONSORT flow chart.

On the day of surgery from the preoperative area, an intravenous line was secured with an 18 g cannula. Saturation of peripheral oxygen (SpO₂), blood pressure, and Electrocardiogram (ECG) monitors were attached. In the case of the infrainguinal group (group I), the linear transducer probe was placed transversely over the inguinal

fold while the patient was supine. The femoral nerve and blood vessels were seen at a depth of 2-4 cm. On the other hand, the iliopsoas muscle and iliac fascia were identified. A 100 mm, 22G stimplex needle was introduced through an in-plane technique [9]. Upon needle penetration of the fascia, a sense of pop was elicited, and the fascia appeared to visually retract on the ultrasound image. After negative aspiration, 1-2 mL of local anaesthetic was injected, and the separation of the iliac fascia from the iliopsoas muscle with the medial extension of the local anaesthetic to the femoral nerve and laterally towards the iliac crest was observed. A total of 40 mL of ropivacaine 0.2% was injected.

In the suprainguinal group (group S), after positioning the patient supine, a linear ultrasound probe was placed in the sagittal plane over the inguinal ligament to obtain an image of the Anterior Superior Iliac Spine (ASIS). The probe was slid medially to identify the “bow tie sign” formed by the internal oblique medially and sartorius laterally. A 100 mm 22 G stimplex needle was introduced through the in-plane technique. The fascia iliaca was penetrated and hydro dissected, separating it from the iliacus muscle [9]. Since the deep circumflex artery lies superficial to the iliac fascia, upward movement of this artery after injection was used as an indicator of successful penetration of the iliac fascia. A total of 40 mL of 0.2% ropivacaine was injected.

After 30 minutes, the patient was shifted to the operating room. Subarachnoid block was given with 2.4 mL of 0.5% hyperbaric bupivacaine. Spinal block was assessed by the motor (modified Bromage score) and sensory examination. The severity of postoperative pain was measured and recorded using a 10 cm VAS at intervals of 2, 6, 12, and 24 hours. If the VAS score was more than 4, rescue analgesia was given. An injection of paracetamol, 1 gm was given as intravenous infusion for 10 to 15 minutes [9]. Duration of analgesia was taken as the first request for analgesia from the time of nerve block. The total amount of intravenous paracetamol given was also recorded.

Patients were closely observed postoperatively for 24 hours for delirium and other complications. Delirium was diagnosed by the Confusion Assessment Method [10] using the following criteria: (a) acute onset and fluctuating course; (b) inattention; (c) disorganised thinking; and (d) altered level of consciousness [11]. The presence of the above features was used to score delirium, which was subsequently managed by standard institutional protocols. All assessments were conducted by the duty consultants, who were not involved in the patient's management in the operating theatre and were blind to the patient's group assignment. The principal investigator collected the data. All gathered data was subjected to appropriate statistical analysis.

STATISTICAL ANALYSIS

Statistical analysis was carried out by using Statistical Package for the Social Sciences (SPSS) version 20.0. Qualitative (categorical) variables were represented by frequency and percentage. To depict quantitative variables, mean and standard deviation were utilised. Chi-square or Fisher's exact test was performed to compare qualitative variables between the groups. Independent sample t-test/Mann-Whitney test was performed to compare quantitative variables between the groups. A p-value <0.05 was taken as statistically significant.

RESULTS

The study data analysis was conducted on 60 patients who met the inclusion criteria. Ultrasound-guided FICB and subarachnoid block were successful in all patients. The demographic data of the patients were comparable in terms of age, sex, and ASA status in both groups [Table/Fig-2].

Variable	Group I	Group S	p-value
Age (in years) M±SD	77.3±9.33	73.8±10.5	0.145
Gender n (%)			
Male	8 (26.7)	12 (40.0)	0.273
Female	22 (73.3)	18 (60.0)	
ASA grade n (%)			
I	1 (3.3)	1 (3.3)	0.99
II	18 (60.0)	19 (63.3)	
III	11 (36.7)	10 (33.3)	

[Table/Fig-2]: Demographic profiles of both the groups.

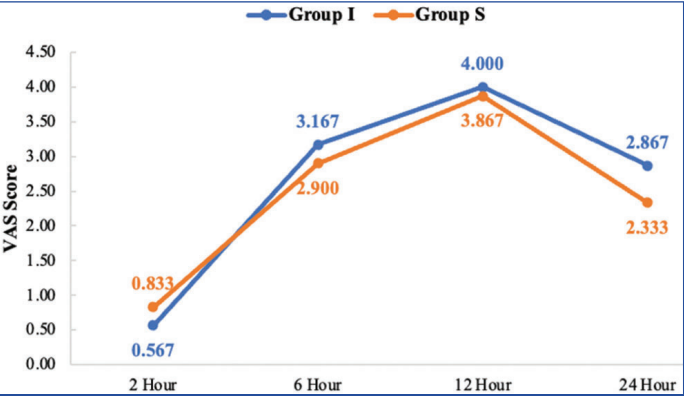
The duration of analgesia was significantly higher in group S compared to group I with a p-value of 0.001 [Table/Fig-3]. Based on VAS scores at 2, 6, 12 and 24 hours, it was found that the suprainguinal group reported significantly less pain (2.333 ± 0.479) at 24 hours than the infrainguinal group (2.867 ± 1.196), with a p-value of 0.047 [Table/Fig-4,5]. The requirement for rescue analgesia over 24 hours was comparable in both groups. In the suprainguinal group, 15 (50.0%) patients received two doses and 15 (50.0%) patients received three doses of paracetamol, while in the infrainguinal group, it was 11 (36.7%) patients and 19 (63.3%) patients, respectively ($p=0.297$) [Table/Fig-6].

Group	Mean±SD	p-value
Group I	385.2±99.39	0.001
Group S	481.7±136.7	

[Table/Fig-3]: Comparison of duration of analgesia between groups.

VAS score	Mean±SD	p-value
2 hours		
Group I	0.567±0.568	0.262
Group S	0.833±0.874	
6 hours		
Group I	3.167±0.950	0.444
Group S	2.900±0.995	
12 hours		
Group I	4.000±1.462	0.975
Group S	3.867±0.860	
24 hours		
Group I	2.867±1.196	0.047
Group S	2.333±0.479	

[Table/Fig-4]: Comparison of VAS score between groups.



[Table/Fig-5]: Comparison of VAS score between group (graph).

Total dose of paracetamol	Group I (n=30)	Group S (n=30)	p-value
2	11 (36.7%)	15 (50.0%)	0.297
3	19 (63.3%)	15 (50.0%)	

[Table/Fig-6]: Comparison of total paracetamol doses between both groups.

The incidence of preoperative delirium was comparable ($p\text{-value}=0.781$) in the two groups. The incidence of postoperative delirium was lower than the preoperative value, but there was no significant difference ($p\text{-value}=0.754$) between the two groups [Table/Fig-7].

Delirium	Group I (n=30)	Group S (n=30)	p-value
Preoperative delirium			
No	20 (66.7%)	21 (70.0%)	0.781
Yes	10 (33.3%)	9 (30.0%)	
Postoperative delirium			
No	23 (76.7%)	24 (80.0%)	0.754
Yes	7 (23.3%)	6 (20.0%)	

[Table/Fig-7]: Comparison of incidence of preoperative and postoperative delirium.

DISCUSSION

In the current study conducted among 60 participants, it was found that the duration of analgesia was significantly higher among the subjects who received postoperative analgesia for proximal femur fractures through the suprainguinal approach (481.7 ± 136.7 minutes) compared to the infrainguinal approach (385.2 ± 99.39 minutes).

Gupta M and Kamath SS, provided a comparable result where they compared ultrasound-guided infrainguinal FICB with that of the Femoral Nerve Block (FNB) in cases of proximal femoral fracture. The analgesia sustained about 7.1 ± 2.1 hours in the FICB group compared to 5.2 ± 0.7 hours in the FNB group [12]. Kumar K et al., showed that the time to the first Patient Controlled Analgesia (PCA) morphine was 356.28 ± 33.32 minutes in the suprainguinal group, while it was 291.48 ± 37.17 minutes in the infrainguinal group [13]. However, Bansal K et al., compared the two methods in above knee procedures and found that the infrainguinal group's time of the first analgesic request (5.63 ± 3.9 hours) was more compared to the suprainguinal group (4.63 ± 4.0 hours), but the difference was not statistically significant [9].

The VAS score was similar between the groups at 2, 6, and 12 hours. The VAS score at 24 hours was significantly less (2.333 ± 0.479) in the suprainguinal group compared to the infrainguinal group (2.867 ± 1.196). Kumar K et al., found a significant reduction in the suprainguinal group's VAS score at six hours. However, the VAS score remained unchanged within the 12- and 24-hour periods [13]. A statistically significant difference in the VAS score at 12 and 20 hours was observed between the suprainguinal group and the infrainguinal group by Bansal K et al., [9].

In the present study, 2 and 3 doses of paracetamol were given to 50.0% each in the suprainguinal group, while in the infrainguinal group it was 36.7% and 63.3%, respectively. Even though paracetamol consumption was less in the suprainguinal group, the difference was not statistically significant. In the Kumar K et al., study, postoperative morphine consumption was significantly less in the suprainguinal group, and Bansal K et al., found that total tramadol consumption in the first 24 hours was reduced to 77.1% in the suprainguinal group and 54.2% in the infrainguinal group [9,13].

In the present study, 33.3% of patients in the infrainguinal and 30% of patients in the suprainguinal group had preoperative delirium. This may be because most of the patients in this study were above 65 years old. Additionally, 36.7% of patients in the infrainguinal group and 33.3% in the suprainguinal group belonged to ASA grade III (severe systemic diseases) and may be on multiple medications. The severe pain associated with these fractures can also contribute to preoperative delirium. When considering the incidence of postoperative delirium, 23.3% of patients in the infrainguinal group and 20% of patients in the suprainguinal group had delirium. Even though the incidence was less than the preoperative value in either group, it was not statistically significant.

Wennberg P et al., examined the impact of FICB on postoperative delirium in patients with hip fractures and found that the procedure did not affect the patient's cognitive status [14]. Steenberg J et al., also found insufficient evidence of the relationship between FICB and the incidence of delirium in hip fracture patients [15]. Similarly, Zhang J et al., demonstrated that FICB can reduce the development of postoperative delirium in patients undergoing total hip arthroplasty [16]. None of the studies compared the incidence of postoperative delirium in the suprainguinal and infrainguinal groups.

Weinstein SM et al., found that regional anaesthesia decreases the incidence of delirium compared to general anaesthesia, and the use of intraoperative opioids increases the incidence of delirium [17]. However, Sica R et al., found that uncontrolled pain may be a more crucial factor for postoperative delirium than opioid consumption, particularly among patients who are opioid tolerant [18]. Paracetamol, being a cyclooxygenase inhibitor, reduces cognitive impairment through its antioxidant activity [19]. Subramanian B et al., showed a decrease in the occurrence of delirium in patients who received paracetamol compared to placebo after cardiac surgery [20]. Hence, using a multimodal opioid-sparing analgesia regime may be an optimal option to reduce postoperative delirium.

The severe pain associated with proximal femoral fractures may lead to perioperative delirium, chronic pain, and delay in the postoperative recovery process. Managing the pain perioperatively among patients with senility and multiple co-morbidities is a challenge for the anaesthesiologist. The lumbar plexus block is thought to be an efficient technique for regional anaesthesia. Nonetheless, patients who have a proximal femoral fracture may find it difficult to be positioned for this block. The lumbar plexus can be approached anteriorly by FICB, which was initially described by Dalen in 1989 [21]. For surgical procedures involving the femur and hip joint, it remains a commonly used regional anaesthetic technique [22]. With the advent of ultrasound, an infrainguinal approach can be done under direct visualisation.

The ultrasound-guided suprainguinal fascia iliaca block, first introduced by Hebbard, involves inserting a needle about 2-4 cm below the inguinal ligament and directing it towards the fascia iliaca located above the inguinal ligament. Desmet M et al., used a more proximal needle insertion site above the inguinal ligament and injected the drug after observing the "bowtie" appearance of the muscles [23]. Vermeylen K et al., did further studies on the amount of drug volume needed for the successful blockade of all three nerves. It showed the requirement of 40 mL of the drug for effective blocking of three nerves [24]. Zhang FF et al., studied the safety of different concentrations of ropivacaine in elderly patients receiving a fascia iliaca block and suggested a lower concentration may be a safer option for a single large volume of FICB [25].

These findings demonstrate that FICB provides effective analgesia, reducing the occurrence of cognitive impairment. The fracture fixation was done under spinal anaesthesia. For rescue analgesia, paracetamol alone was used and did not use any opioids throughout the preoperative or postoperative period.

Limitation(s)

The investigation of the pain score on mobilisation was not done. This was a unicentric trial, and hence further multicentric trials are needed to confirm these findings.

CONCLUSION(S)

The analgesic efficacy of the suprainguinal FICB surpasses that of the infrainguinal fascia iliaca block, exhibiting longer-lasting pain

relief and diminished pain intensity at 24 hours. No notable distinction was observed in total paracetamol consumption and incidence of delirium.

REFERENCES

- Maffulli N, Aicale R. Proximal femoral fractures in the elderly: A few things to know, and some to forget. *Medicina (Kaunas)*. 2022;58(10):1314.
- Buchan TA, Sadeghirad B, Schmutz N, Goettel N, Foroutan F, Couban R, et al. Preoperative prognostic factors associated with postoperative delirium in older people undergoing surgery: Protocol for a systematic review and individual patient data meta-analysis. *Syst Rev*. 2020;9(1):261.
- Beverly A, Kaye AD, Ljungqvist O, Urman RD. Essential elements of multimodal analgesia in Enhanced Recovery After Surgery (ERAS) guidelines. *Anaesthesiol Clin*. 2017;35(2):e115-43.
- Sarkies MN, Testa L, Carrigan A, Roberts N, Gray R, Sherrington C, et al. Perioperative interventions to improve early mobilisation and physical function after hip fracture: A systematic review and meta-analysis. *Age Ageing*. 2023;52(8):afad154.
- Gottlieb M, Long B. Peripheral nerve block for hip fracture. *Acad Emerg Med*. 2021;28(10):1198-99.
- Fujihara Y, Fukunishi S, Nishio S, Miura J, Koyanagi S, Yoshiya S. Fascia iliaca compartment block: Its efficacy in pain control for patients with proximal femoral fracture. *J Orthop Sci*. 2013;18(5):793-97.
- Wang YL, Liu YQ, Ni H, Zhang XL, Ding L, Tong F, et al. Ultrasound-guided, direct suprainguinal injection for fascia iliaca block for total hip arthroplasty: A retrospective study. *World J Clin Cases*. 2021;9(15):3567-75.
- Stevens M, Harrison G, McGrail M. A modified fascia iliaca compartment block has significant morphine-sparing effect after total hip arthroplasty. *Anaesth Intensive Care*. 2007;35(6):949-52.
- Bansal K, Sharma N, Singh MR, Sharma A, Roy R, Sethi S. Comparison of suprainguinal approach with infrainguinal approach of fascia iliaca compartment block for postoperative analgesia. *Indian J Anaesth*. 2022;66(Suppl 6):S294-99.
- Green JR, Smith J, Teale E, Collinson M, Avidan MS, Schmitt EM, et al. Use of the confusion assessment method in multicentre delirium trials: Training and standardisation. *BMC Geriatr*. 2019;19(1):107.
- Aldwikat RK, Manias E, Tomlinson E, Amin M, Nicholson P. Delirium screening tools in the post-anaesthetic care unit: A systematic review and meta-analysis. *Aging Clin Exp Res*. 2022;34(6):1225-35.
- Gupta M, Kamath SS. Comparison of preoperative ultrasound guided fascia iliaca block versus femoral nerve block for proximal femur fractures before positioning for spinal anaesthesia: An observational study. *Korean J Pain*. 2020;33(2):138-43.
- Kumar K, Pandey RK, Bhalla AP, Kashyap L, Garg R, Darlong V, et al. Comparison of conventional infrainguinal versus modified proximal suprainguinal approach of fascia iliaca compartment block for postoperative analgesia in total hip arthroplasty: A prospective randomised study. *Acta Anaesthesiol Belg*. 2015;66(3):95-100.
- Wennberg P, Möller M, Herlitz J, Kenne Sarenmalm E. Fascia iliaca compartment block as a preoperative analgesic in elderly patients with hip fractures- effects on cognition. *BMC Geriatr*. 2019;19(1):252.
- Steenberg J, Möller AM. Systematic review of the effects of fascia iliaca compartment block on hip fracture patients before operation. *Br J Anaesth*. 2018;120(6):1368-80.
- Zhang J, Niu G, Wang X, Li W. Effect of fascia iliaca compartment block on postoperative delirium in elderly patients undergoing total hip arthroplasty. *Chinese Journal of Anaesthesiology*. 2020;12:655-59.
- Weinstein SM, Poultsides L, Baaklini LR, Mörwald EE, Cozowicz C, Saleh JN, et al. Postoperative delirium in total knee and hip arthroplasty patients: A study of perioperative modifiable risk factors. *Br J Anaesth*. 2018;120(5):999-1008.
- Sica R, Wilson JM, Kim EJ, Culley DJ, Meints SM, Schreiber KL. The relationship of postoperative pain and opioid consumption to postoperative delirium after spine surgery. *J Pain Res*. 2023;16:287-94.
- Lalert L, Maneesri le-Grand S, Techarang T, Huntula S, Punsawad C. Neuroprotective effect of low-dose paracetamol treatment against cognitive dysfunction in d-galactose-induced aging mice. *Heliyon*. 2022;8(10):e11108.
- Subramaniam B, Shankar P, Shaefi S, Mueller A, O'Gara B, Banner-Goodspeed V, et al. Effect of intravenous acetaminophen vs placebo combined with propofol or dexmedetomidine on postoperative delirium among older patients following cardiac surgery: The DEXACET randomised clinical trial. *JAMA*. 2019;321(7):686-96.
- Dalens B, Vanneville G, Tanguy A. Comparison of the fascia iliaca compartment block with the 3-in-1 block in children. *Anaesth Analg*. 1989;69(6):705-13.
- Kacha NJ, Jadeja CA, Patel PJ, Chaudhari HB, Jivani JR, Pithadia VS. Comparative study for evaluating efficacy of fascia iliaca compartment block for alleviating pain of positioning for spinal anaesthesia in patients with hip and proximal femur fractures. *Indian J Orthop*. 2018;52(2):147-53.
- Desmet M, Vermeylen K, Van Herreweghe I, Carlier L, Soetens F, Lambrecht S, et al. A longitudinal supra-inguinal fascia iliaca compartment block reduces morphine consumption after total hip arthroplasty. *Reg Anaesth Pain Med*. 2017;42(3):327-33.

[24] Vermeylen K, Soetens F, Leunen I, Hadzic A, Van Boxtael S, Pomés J, et al. The effect of the volume of supra-inguinal injected solution on the spread of the injectate under the fascia iliaca: A preliminary study. J Anaesth. 2018;32(6):908-13.

[25] Zhang FF, Lv C, Yang LY, Wang SP, Zhang M, Guo XW. Pharmacokinetics of ropivacaine in elderly patients receiving fascia iliaca compartment block. Exp Ther Med. 2019;18(4):2648-52.

PARTICULARS OF CONTRIBUTORS:

1. Assistant Professor, Department of Anaesthesiology, Malabar Medical College and Research Centre, Calicut, Kerala, India.
2. Assistant Professor, Department of Anaesthesiology, Malabar Medical College and Research Centre, Calicut, Kerala, India.
3. Associate Professor, Department of Anaesthesiology, Malabar Medical College and Research Centre, Calicut, Kerala, India.
4. Professor, Department of Anaesthesiology, Malabar Medical College and Research Centre, Calicut, Kerala, India.
5. Professor and Head, Department of Anaesthesiology, Malabar Medical College and Research Centre, Calicut, Kerala, India.
6. Associate Professor, Department of Anaesthesiology, Malabar Medical College and Research Centre, Calicut, Kerala, India.
7. Junior Resident, Department of Anaesthesiology, Malabar Medical College and Research Centre, Calicut, Kerala, India.
8. Junior Resident, Department of Anaesthesiology, Malabar Medical College and Research Centre, Calicut, Kerala, India.

NAME, ADDRESS, E-MAIL ID OF THE CORRESPONDING AUTHOR:

Dr. Moona,
Professor, Department of Anaesthesiology, Malabar Medical College and Research Centre, Ulliyeri, Modakkallur, Calicut-673315, Kerala, India.
E-mail: moonakad@gmail.com

PLAGIARISM CHECKING METHODS: [\[Jain H et al.\]](#)

- Plagiarism X-checker: Jul 20, 2024
- Manual Googling: Aug 23, 2024
- iThenticate Software: Oct 10, 2024 (14%)

ETYMOLOGY: Author Origin

EMENDATIONS: 6

AUTHOR DECLARATION:

- Financial or Other Competing Interests: None
- Was Ethics Committee Approval obtained for this study? Yes
- Was informed consent obtained from the subjects involved in the study? Yes
- For any images presented appropriate consent has been obtained from the subjects. NA

Date of Submission: Jul 19, 2024
Date of Peer Review: Aug 24, 2024
Date of Acceptance: Oct 11, 2024
Date of Publishing: Nov 01, 2024